



Pituitary adenoma with hypothalamic involvement: a case of 'atypical' atypical depression

Abstract

Pituitary tumours are known to be associated with neuropsychiatric manifestations; however, it is uncommon for the manifestations to be the sole presenting symptoms. We report a case of 29-year-old male presenting with low mood, decreased attention, forgetfulness, increased sleep, and increased appetite of three months duration. Diagnosis of moderate depression episode with atypical features was considered and started on antidepressant Bupropion up to 300 mg/day to which he showed no improvement. Considering the atypical features and poor response to antidepressants, magnetic resonance imaging (MRI) brain was done which showed pituitary macro adenoma compressing on the hypothalamus. After surgical removal of the tumour, patient's symptoms improved. Hypothalamic involvement in this patient possibly led to manifestations mimicking atypical depression. This case highlights the importance of considering organic aetiologies in patients presenting with atypical depression.

Keywords: Neoplasms. Neuropsychiatry. Neuropsychology. Prolactinoma.

**Manjunadh Muraleedharan¹,
Rishikesh V Behere²**

*¹DM Resident in Geriatric Mental Health,
Department of Geriatric Mental Health,
King George's Medical University, Lucknow,
Uttar Pradesh, India, ²Associate Professor,
Department of Psychiatry, Kasturba Medical
College, Manipal, Karnataka, India*

Correspondence: Dr. Manjunadh
Muraleedharan, Room No. B206, Gautam
Buddha Hostel, King George's Medical
University, Lucknow-226003, Uttar Pradesh,
India. manjunadh1987@gmail.com

Received: 13 January 2017

Revised: 4 October 2017

Accepted: 4 October 2017

Epub: 6 July 2018

DOI: 10.5958/2394-2061.2018.00021.6

INTRODUCTION

Pituitary tumours represent ten to 25% of all intracranial neoplasms.[1] The most characteristic presenting features of pituitary adenomas include inappropriate pituitary hormone secretion and visual field deficits.[2] Pituitary patients may experience emotional problems as a result of long-term effects that the pituitary tumour itself, treatment, and/or hormonal changes have on the hypothalamic-pituitary-end organ axis.

The neuropsychological impairment caused by these tumours has been documented to cause fatigue, apathy, deficit in executive functioning, verbal reasoning, and visual memory.[1] Pituitary tumours are known to be associated with neuropsychiatric manifestations; however, it is uncommon for the manifestations to be the sole presenting symptoms. We report a case of 29-year-old male presenting with atypical depressive symptoms due to a pituitary prolactinoma compressing on hypothalamus.

CASE

Mr A was a 29-year-old unmarried male from lower economic status educated up to eight standard with no family history of mental illness, working as a hotel waiter presented at Department of Psychiatry, Kasturba Medical College Hospital, Manipal, Karnataka, India with three months history of forgetfulness (missing his orders), low mood, decreased attention, fatigue, lack of motivation, increased appetite and sleep. He had no significant past history of mental or physical

illness. There was no history of any substance abuse or addiction and no history of loss of consciousness, head injury. He was well adjusted pre-morbidly.

Mental status examination at the time of presentation showed impairment in concentration, short-term memory deficits, depressive cognitions related to his occupational dysfunction. His physical examination was normal except that he was obese with a body mass index (BMI) of 30.

His Hamilton Depression Rating Scale (HDRS)[3] score was 14 and Mini Mental State Examination (MMSE)[4] score was 23 with predominant deficit in concentration, and difficulty in registering and recall. His laboratory investigations including complete blood profile, thyroid profile, renal function test, liver function test, and vitamin B12 were normal. Diagnosis of moderate depressive episode according to the tenth revision of the International Statistical Classification of Diseases and Related Health Problems (ICD-10)[5] diagnostic criteria was made and was started on antidepressant Bupropion up to a dose of 300 mg/day.

He was followed up on outpatient basis; after a course of four weeks, he showed no improvement in symptoms. Considering the atypical features, cognitive deficits, and poor response to antidepressant, magnetic resonance imaging (MRI) brain was done which showed pituitary macro adenoma compressing on the hypothalamus (Figure 1a, 1b, 1c). His prolactin level was 1020 ng/ml (normal range 3-15), detailed visual field examination showed bitemporal hemianopsia.

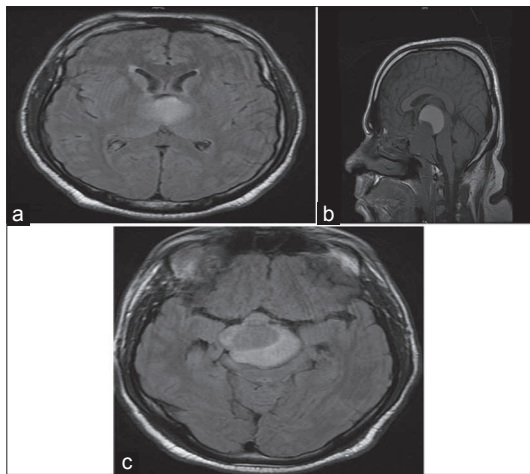


Figure 1(a-c): Magnetic resonance imaging (MRI) brain showing pituitary macro adenoma compressing on the hypothalamus

He was referred to neurosurgery department for further management. After surgical removal of the tumour, patient's symptoms improved. Histology of the tumour showed sparsely granulated prolactin secreting adenoma.

DISCUSSION

The hypothalamic-pituitary tract provides significant afferent input to the mediodorsal nucleus of the thalamus and any perturbation in hypothalamic-pituitary function will affect the frontal-sub cortical circuits and cause apathy, fatigue.[6]

His disturbances in vegetative functions and short term memory can be explained since the tumour involves hypothalamus compromising its functions.[7]

Symptomatology was mostly due to disturbance in cognitive functions and vegetative functions leading to fatigue, apathy rather than symptoms found in classical depression like anhedonia, feelings of guilt.

This case highlights the importance of considering organic causes in patients presenting with atypical depression. It also envisages the importance of imaging when the symptoms are atypical with a poor response to pharmacotherapy.

REFERENCES

1. Fava GA. Affective disorders and endocrine disease. New insights from psychosomatic studies. *Psychosomatics*. 1994;35:341-53.
2. Weitzner MA. Neuropsychiatry and pituitary disease: an overview. *Psychother Psychosom*. 1998;67:125-32.
3. Hamilton M. A rating scale for depression. *J Neurol Neurosurg Psychiatry*. 1960;23:56-62.
4. Folstein MF, Folstein SE, McHugh PR. "Mini-mental state". A practical method for grading the cognitive state of patients for the clinician. *J Psychiatr Res*. 1975;12:189-98.
5. World Health Organization. The ICD-10 classification of mental and behavioural disorders: clinical descriptions and diagnostic guidelines. 10th rev. Geneva: World Health Organization; 1992.
6. Sablowski N, Pawlik K, Lüdecke DK, Herrmann HD. Aspects of personality in patients with pituitary adenomas. *Acta Neurochir (Wien)*. 1986;83:8-11.
7. Burman P, Broman JE, Hetta J, Wiklund I, Erfurth EM, Hagg E, *et al*. Quality of life in adults with growth hormone (GH) deficiency: response to treatment with recombinant human GH in a placebo-controlled 21-month trial. *J Clin Endocrinol Metab*. 1995;80:3585-90.

Muraleedharan M, Behere RV. Pituitary adenoma with hypothalamic involvement: a case of 'atypical' atypical depression. *Open J Psychiatry Allied Sci*. 2018;9:164-5. doi: 10.5958/2394-2061.2018.00021.6. Epub 2017 Nov 6.

Source of support: Nil. **Declaration of interest:** None.